

# Radiographic view of adhesive layer and relationship with marginal leakage in class II composite resin restorations

## *Visualização radiográfica da camada de adesivo e relação com infiltração marginal em restaurações classe II de resina composta*

Márcia Bueno<sup>1</sup>, Rafael Ratto de Moraes<sup>2</sup>, Eduardo Costa de Azevedo<sup>3</sup>, Rudimar Antônio Baldissera<sup>1</sup>

### ABSTRACT

This study assessed the influence of the application of bonding agents prior to or after matrix and wedge placement in the radiographic view of the adhesive layer in cervical walls of Class II composite resin restorations and correlated the findings with marginal leakage. Standard cavities were prepared in the mesial and distal faces of human molars, with cervical margins placed in dentin/cementum. Restorations were made using metallic matrix bands and wooden wedges. The microhybrid composite Filtek Z250 (3M ESPE) and two adhesive systems – Single Bond 2 (SB-3M ESPE) and Scotchbond Multi-Purpose (SMP-3M ESPE) – were used, thus defining five groups (n= 12): [SB1] and [SMP1]- matrix and wedge placed after bonding application; [SB2] and [SMP2]-matrix and wedge placed prior to bonding application; [Control] – restorations without adhesive system. Bitewing radiographs from each tooth were obtained and the view or not of the adhesive layer in the cervical wall of each restoration was observed under magnification (40x). Specimens were thermalcycled and dye penetration (0.5% basic fuchsin) evaluated under magnification (40x). Data were submitted to Kruskal-Wallis and Spearman correlation tests (p=0.05). The placement of matrix and wedge before bonding agent application increased the view of the adhesive layer only for SB (p<0.001). Matrix did not influence marginal leakage, and no significant relationship between radiographic view of adhesive layer and marginal leakage (r=-0.020; p =0.877) could be observed. In conclusion, SB presented better sealing ability than SMP (p<0.01).

**Uniterms:** Dentin-bonding agents. Dental leakage. Dental restoration permanent.

### INTRODUCTION

Cervical adaptation is of critical importance for the success of restorative treatments, considering that good marginal integrity, mainly in approximal areas, minimizes problems such as plaque retention, periodontal inflammation, and marginal leakage<sup>1</sup>. The use of a matrix and wedge is indispensable in obtaining the appropriate marginal fit, restoration contour, contact to the adjacent teeth, and proper condensation of the restorative material. Nowadays, metal matrices and wooden wedges are routinely used for posterior composite resin restorations<sup>2</sup>. However, it has been

speculated that the placement of matrix bands prior to the application of a bonding agent could either increase the adhesive layer thickness or lead to an insufficient bonding of the outer portion of the cervical cavity wall<sup>3</sup>, compromising the marginal integrity of restorations.

Nevertheless, the clinical corroboration of an adequate approximal adaptation is still dependent on instruments and accessory means. Because of a poor view of the area, a mirror, a probe, and dental floss are used to allow an adequate assessment of this area; however, these methods are not totally reliable.

---

<sup>1</sup>Professor; UFPel

<sup>2</sup>Graduate Student, UNICAMP

<sup>3</sup>Graduate Student; UFPel

In fact, bitewing radiographs are usually more accurate in evaluating the cervical margin quality<sup>4</sup>, although x-ray observations are dependent on both the radiographic technique and material radiopacity<sup>5</sup>.

Radiopaque resins are strongly indicated for composite restorations<sup>4-5</sup>. However, the composite resin is applied in association with radiolucent bonding agents, which could hinder the radiographic evaluation of the cervical area<sup>1</sup>. Kreulen et al.<sup>4</sup>, in a clinical study, detected the presence of radiolucent zones adjacent to 53% of composite fillings. These radiolucent areas could be a consequence of gap formation in the cervical wall<sup>6</sup>, or a thick layer of adhesive resin<sup>7</sup>, and could lead to a false radiographic diagnosis of secondary decay<sup>5, 8-9</sup> or a misinterpretation of underfilled restorations<sup>1</sup>.

Furthermore, the role of the thickness of the adhesive layer on the performance of composite restorations (*e.g.* on sealing ability) is still not well-established<sup>10</sup>. Therefore, the purpose of this study was to investigate the influence of placing a matrix and wedge prior to or after the application of the bonding system on the radiographic view of the adhesive layer in cervical walls of Class II composite restorations as well as to correlate the findings with marginal leakage in dentin/cementum margins.

## MATERIALS AND METHODS

### Samples preparation

Thirty extracted, caries-free human molars were obtained through a protocol approved by the institutional review board of the School of Dentistry/UFPel, and stored in a sodium azide solution, at 4°C, for no more than 45 days. In each tooth, a standard Class II cavity (4mm width x 4mm length x 6mm deep) was prepared in both mesial and distal proximal faces, using #245 carbide burs (KG Sorensen, Barueri, SP) at high-rotation speed, under air-water cooling. Burs were replaced after every five preparations to ensure high cutting efficacy. All cavities presented occlusal margins placed in enamel and cervical margins in dentin/cementum.

In order to best simulate the clinical situation, the teeth were mounted in artificial jaws, allowing for the placement of restorations in approximal contact with the adjacent teeth. Fillings were carried out using a microhybrid composite (Filtek Z250-3M ESPE, St. Paul, MN, USA), shade A2, together with two total-etching adhesive systems: Single Bond 2 (SB-3M ESPE) and Scotchbond Multi-Purpose (SMP-3M ESPE). Materials' composition is shown in Table 1.

**Table 1-** Materials used in the study.

Material	Manufacturer	Main components
Filtek Z250	3M ESPE (lot: 14081)	Bis-GMA, UDMA, Bis-EMA, TEGDMA zirconia/silica (0.01-3.5 µm, 60vol%)
Single Bond 2	3M ESPE (lot: 9CY)	Bis-GMA, HEMA polyalkenoic acid copolymers, water, ethanol, colloidal silica
Scotchbond Multi-Purpose	3M ESPE (lot: 04121)	<i>Primer:</i> HEMA, polyalkenoic acid copolymers, water <i>Bond:</i> Bis-GMA, HEMA

Bis-GMA: bisphenol-A glycidyl dimethacrylate; UDMA: urethane dimethacrylate; Bis-EMA: bisphenol-A ethoxylated dimethacrylate; TEGDMA: triethylene glycol dimethacrylate; HEMA: hydroxyethyl methacrylate.

All restorative procedures followed the manufacturer's instructions, using metal matrices and wooden wedges, as well as microbrushes for adhesive application. Absorbent paper was used to remove the excess dentin moisture. In SB1 and SMP1 groups, the matrix and wedge were placed after bonding application; in SB2 and SMP2 groups, the matrix and wedge were placed prior to the adhesive application. The control group was defined by restorations without using an adhesive system. Twelve restorations were crafted for each group. The composite resin was set in the cavity in increments of 2 mm, each light-activated for 20 s (XL3000, 3M ESPE, 600 mW/cm<sup>2</sup>). The occlusal

surfaces were finished using multi-laminated burs (KG Sorensen), while the approximal faces were finished using a scaler (Duflex SS White, Rio de Janeiro, RJ), until probing and flossing failed to reveal any catches. Polishing procedures were performed using aluminum oxide discs (Sof-Lex system, 3M ESPE) and abrasive strips (3M ESPE).

### Radiographic evaluation

Specimens were then removed from the artificial jaw and individually embedded in acrylic resin (Clássico Artigos Odontológicos, São Paulo, SP), creating molds that allowed one to position the samples for standardized bitewing radiographs

(UltraSpeed films, Eastman Kodak Co., Rochester, NY, USA, 10 mA, 60 kV, 0.4 s), with a constant 10 cm film-focus distance. Film processing was carried out in an automatic developing machine (AT 2000, Air Techniques Inc., Hicksville, NY, USA). Radiographic images were then assessed blindly under magnification (40x) by two examiners so as to view or not radiolucent images of the adhesive layer in the cervical walls of the fillings.

**Marginal leakage test**

Apical openings were occluded with epoxy resin (Poxilina Acapol, Buenos Aires, Argentina), and samples were thermalcycled (500 cycles between 5 ± 2°C and 55 ± 2°C, dwell time of 30 s). Next, all tooth surfaces were isolated with a double layer of nail varnish (except restorations and 0.5 mm surrounding them) and the specimens immersed in 0.5% basic fuchsin solution for 24 h, at room temperature, followed by washing in tap water for 24 h. Afterwards, each surface was sectioned longitudinally through the center of the restoration. Cervical margins were then evaluated blindly under magnification (40x) by two examiners to verify the presence or absence of dye along the

cervical cavity walls.

**Statistical analysis**

Data from the radiographic and leakage assessments were submitted separately to non-parametric Kruskal-Wallis tests (p=0.05). Relationships between the radiographic and leakage data was analyzed by Spearman’s correlation test.

**RESULTS**

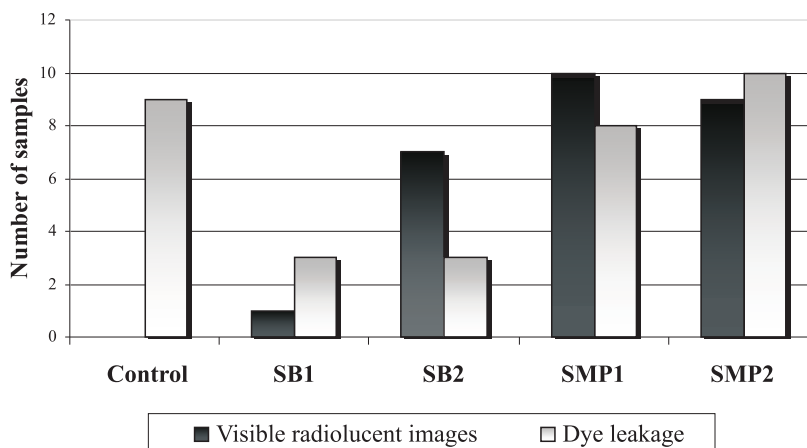
**Radiographic evaluation**

Results are shown in Table 2 and Graph 1. Radiolucent images of the adhesive layer could not be observed adjacent to restorations of the control group (0%). SB1 was statistically similar to the control group, with only 8.3% of the samples with radiographic visible adhesive layers. In addition both of these groups showed significantly less visible layers than all the remaining groups (p<0.00); SB2 (58.3%), SMP1 (83.3%), and SMP2 (75%) were statistically similar. The placement of a matrix and wedge prior to the bonding agent application only significantly increased the view of the adhesive layer for SB (p<0.00), whereas SMP showed a high number of samples with radiolucent images for all groups.

**Table 2-** Total number of samples per group with radiographically visible images (RVI) of the adhesive layer and dye leakage (DL) along the cervical cavity wall.

Group	RVI	DL
Control	0 B	9 a
SB1	1 B	3 b
SB2	7 A	3 b
SMP1	10A	9 a
SMP2	9 A	10a

Distinct letters in the same column indicate statistically significant differences. A,B: differ at p < 0.001; a,b: differ at p < 0.01.



**Graph 1-** Comparison between radiographic visible images of the adhesive layer and dye penetration along the cervical cavity walls for each group. The Spearman’s test detected no significant relationship between these two evaluations (r=-0.020; p=0.87).

## Marginal leakage

Leakage results are shown in Table 2 and Graph 1. SMP1 (75%), SMP2 (83.3%), and control (75%) groups were similar to each other, but all of them exhibited significantly more samples with dye penetration when compared to SB1 (25%) and SB2 (25%) ( $p < 0.01$ ). SB1 and SB2 showed similar sealing outcomes. The application of bonding agent after matrix placement did not influence marginal leakage.

The correlation test detected no significant relationship between the radiographic detection of visible images of the adhesive layer and marginal leakage ( $r = -0.020$ ;  $p = 0.877$ ). In addition, regardless of the moment of adhesive application, SB showed significantly better sealing ability than did SMP ( $p < 0.01$ ).

## DISCUSSION

The use of a matrix and wedge aids in the isolation of the operating area and improves both adaptation and condensation of the restorative material, mainly in deep cervical areas<sup>2</sup>. However, it has been speculated that the placement of a matrix strip prior to the bonding agent application could increase the thickness and, as a result, the radiographic view of this layer<sup>3</sup>. A thick layer of radiolucent adhesive may appear on a radiograph as a radiolucent zone between the cavity wall and the radiopaque composite. Thicknesses of adhesive layers vary among bonding systems, and those exceeding 40  $\mu\text{m}$  could be accurately detected on radiographs<sup>7</sup>.

According to Hardison et al.<sup>9</sup>, radiographically visible halos, which could result from thick layers of adhesive resin, may indicate a compromised restoration. Therefore, the primary aim of this study was to assess the influence of time in which the adhesive was applied on radiographic visualization of adhesive layer. The current outcomes indicate that the presence of the matrix in the moment of the adhesive application significantly increased the radiographic thickness of SB layers, so much so that SB2 showed significantly more visible areas than SB1. It could be speculated that this outcome is related to a concentration of bonding resin in the cervical wall as well as to an inadequate removal of the adhesive excess when the matrix was in place.

The influence of the thickness of the adhesive layer on properties of fillings is still uncertain. Some authors link thick layers to good marginal sealing and high bond strengths<sup>10-11</sup> in a hypothesis that thicker films would allow for better composite adaptation, improving stress distribution in the bonding assembly. Conversely, other studies indicate that thick layers

might compromise the restoration quality<sup>1,7</sup> since bonding agents undergo higher polymerization shrinkage and thermal expansion/contraction than do composites. Thus, margins that were initially sealed could break open over the course of time<sup>9</sup>, and the resultant leakage could pose a risk to marginal staining, pulp sensitivity, and secondary caries<sup>12</sup>.

On the other hand, SMP groups presented a high number of samples with radiolucent images in both SMP1 and SMP2 groups, *i.e.*, when the adhesive was applied either before or after the placement of the matrix. Choi et al.<sup>11</sup> observed that SMP creates a layer around 20-300  $\mu\text{m}$ -thick and that a double layer could become 5x thicker, which would be directly related to its appearance on radiographs. A possible explanation for this is the fact that SMP is a three-step system, that is, the primer and the bond resin are available separately in two bottles, which could create a thick layer during the application of this system. On the other hand, as SB is a two-step, self-priming system, the primer and the bond resin are mixed together in a single bottle. Therefore, the volume of adhesive dispensed in the cavity is probably lower when compared to SMP.

In addition, it can be speculated that the instrument used for the application of the bonding resin could also interfere in the thickness of the resulting layer. Microbrushes deliver high adhesive volumes and do not allow for an exact control of use, which could also be related to the present results. According to Carvalho et al.<sup>13</sup>, a fine brush is a more suitable instrument for the application of bonding agents.

Furthermore, SMP showed a poorer sealing ability than did SB. This is probably due to the fact that the SMP primer contains water as a solvent, with a 17.5 mmHg/20°C vapor pressure, while ethanol (SB vehicle) possesses a higher vapor pressure (43.9 mmHg/20°C) and, thus, easier volatilization<sup>14-15</sup>. The present outcomes suggest that the 5s air-dry period for solvent evaporation, following the SMP manufacturer's instructions, might not be sufficient to allow for effective water displacement and effective monomer infiltration, consequently interfering with hybridization and sealing ability<sup>15</sup>. Nonetheless, no significant relationship between the radiographic view of the adhesive layer and marginal leakage could be observed. This finding suggests that thick layers of adhesive do not negatively influence the short-term sealing of composite restorations, which is in agreement with the findings from Choi et al.<sup>11</sup> and Zheng et al.<sup>10</sup>.

Since radiolucent images of the adhesive

layer were not present around all restorations, it seems likely that this radiographic evaluation is technique and material dependent. A technique that leaves an excess bonding agent might cause radiolucent halos on cervical walls, and the failure to blow off the excess of adhesive resin before curing seems a probable cause. Because the observation of translucent zones on radiographs can be associated with thick adhesive layers, secondary caries, or gaps, it remains uncertain if such restorations require replacement. Therefore, clinicians should be aware of replacing restorations only because a radiolucent zone is seen on the radiograph and are further urged to consider other findings for supporting a diagnosis of recurrent decay or lack of filling material.

## CONCLUSION

The influence of the placement of a matrix on bonding procedures proved to be material dependent. Single Bond 2 layers were more accurately detected on radiographs when a matrix and wedge were in place during the bonding agent application. On the other hand, the presence of a matrix did not influence marginal leakage, and there was no significant relationship between the radiographic view of the adhesive layer and microleakage. Furthermore, Scotchbond Multi-Purpose presented more samples with radiographically detectable images as well as poorer sealing ability than did Single Bond 2.

## RESUMO

Este estudo avaliou a influência da aplicação do agente de união antes ou após a colocação de matriz e cunha na visualização radiográfica da camada de adesivo nas margens cervicais de restaurações Classe II de resina composta, e correlacionou os achados com infiltração marginal. Cavidades padronizadas foram preparadas nas faces mesial e distal de molares humanos, com margens cervicais em dentina/cimento. As restaurações foram feitas utilizando matriz metálica e cunhas de madeira. O compósito Filtek Z250 (3M ESPE) e dois sistemas adesivos-Single Bond 2 (SB-3M ESPE) e Scotchbond Multi-Purpose (SMP-3M ESPE)- foram utilizados, definindo cinco grupos (n=12): [SB1] e [SMP1]-matriz e cunha colocadas após a aplicação do adesivo; [SB2] e [SMP2]- matriz e cunha colocadas antes da aplicação do adesivo; [Controle]- restaurações sem sistema adesivo. Radiografias interproximais de cada dente foram obtidas e a visualização ou não da camada de adesivo na parede cervical observada sob aumento (40x). Os espécimes foram termociclosados e a

penetração do corante (fucsina básica 5%) avaliada sob aumento (40x). Os dados foram submetidos aos testes de Kruskal-Wallis e de correlação de Spearman ( $p=0,05$ ). A colocação de matriz e cunha antes da aplicação do adesivo aumentou a visualização da camada apenas para o SB ( $p<0,00$ ). A matriz não influenciou a infiltração marginal, e não houve correlação significativa entre visualização da camada e infiltração ( $r=-0,020$ ;  $p=0,87$ ). O adesivo SB mostrou melhor selamento que o SMP ( $p<0,01$ ).  
**Descritores:** Adesivos dentinários. Infiltração dentária. Restauração dentária permanente.

## REFERENCES

1. Opdam NJ, Roeters FJ, Feilzer AJ, Smale I . A radiographic and scanning electron microscopic study of approximal margins of Class II resin composite restorations placed *in vivo*. J Dent. 1998; 26: 319-27.
2. Mullejans R, Badawi MO, Raab WH, Lang H. An *in vitro* comparison of metal and transparent matrices used for bonded class II resin composite restorations. Oper Dent. 2003; 28: 122-6.
3. Ernst CP, Streicher S, Willershausen B. Marginal adaptation of self-etching adhesives in Class II cavities. J Adhes Dent. 2002; 4: 223-31.
4. Kreulen CM, Van Amerongen WE, Akerboom HB, Borgmeijer PJ, Gruythuysen RJ. Radiographic assessments of Class II resin composite restorations in a clinical study: baseline results. ASDC J Dent Child. 1992; 59: 97-107.
5. Hara AT, Serra MC, Haiter-Neto F, Rodrigues AL Jr. Radiopacity of esthetic restorative materials compared with human tooth structure. Am J Dent. 2001; 14: 383-6.
6. Akerboom HB, Kreulen CM, van Amerongen WE, Mol A. Radiopacity of posterior composite resins, composite resin luting cements, and glass ionomer lining cements. J Prosthet Dent. 1993; 70: 351-5.
7. Opdam NJ, Roeters FJ, Verdonchot EH. Adaptation and radiographic evaluation of four adhesive systems. J Dent. 1997; 25: 391-7.
8. Espelid I, Tveit AB, Erickson RL, Keck SC, Glasspoole EA. Radiopacity of restorations and detection of secondary caries. Dent Mater. 1991; 7: 114-7.

9. Hardison JD, Rafferty-Parker D, Mitchell RJ, Bean LR. Radiolucent halos associated with radiopaque composite resin restorations. *J Am Dent Assoc.* 1989; 118: 595-7.
10. Zheng L, Pereira PN, Nakajima M, Sano H, Tagami J. Relationship between adhesive thickness and microtensile bond strength. *Oper Dent.* 2001; 26: 97-104.
11. Choi KK, Condon JR, Ferracane JL. The effects of adhesive thickness on polymerization contraction stress of composite. *J Dent Res.* 2000; 79: 812-7.
12. Raskin A, D'Hoore W, Gonthier S, Degrange M, Dejou J. Reliability of *in vitro* microleakage tests: a literature review. *J Adhes Dent.* 2001; 3: 295-308.
13. Carvalho RM, Carrilho MR, Pereira LC, Garcia FC, Marquezini Jr L, Silva SM, et al. Sistemas adesivos: fundamentos para aplicação clínica. *Biodonto* 2004; 2: 8-76.
14. Gallo JR, Burgess JO, Xu X. Effect of delayed application on shear bond strength of four fifth-generation bonding systems. *Oper Dent.* 2001; 26: 48-51.
15. Lima FG, Moraes RR, Demarco FF, Del Pino FA, Powers J. One-bottle adhesives: *in vitro* analysis of solvent volatilization and sealing ability. *Braz Oral Res.* 2005; 19: 278-83.