

## Evaluation of temporal bone pneumatization using panoramic radiography and cone beam computed tomography

Alice Souza Villar Cassimiro Fonseca<sup>1</sup>  | Loliza Luiz Figueiredo Houri Chalub<sup>2</sup>  | Vinícius de Carvalho Machado<sup>1</sup>  | Cláudia Borges Brasileiro<sup>2</sup> 

<sup>1</sup>Slice Diagnóstico Volumétrico por Imagem, Belo Horizonte Minas Gerais, Brasil

<sup>2</sup>Faculdade de Odontologia, Universidade Federal de Minas Gerais, Belo Horizonte, Minas Gerais, Brasil

**Aim:** To evaluate the presence and characteristics of pneumatizations in the roof of the mandibular fossa and articular eminence by panoramic radiography and cone beam computed tomography (CBCT).

**Methods:** This study analyzed CBCT images of the temporomandibular joint of 705 patients. In 60 exams, it was possible to compare tomographic with panoramic images. For cases where pneumatization was present, laterality and pattern of manifestation were considered. A chi-square test was used to compare the differences between CBCT and panoramic radiography in the diagnosis of pneumatization.

**Results:** Descriptive analysis revealed a sample profile that was predominantly female (75.9%), with a mean age of 42.6 years ( $\pm 17.4$ ). The presence of pneumatizations in the roof of the mandibular fossa and articular eminence in CBCT images was identified in 330 (46.8%) and 154 (21.8%) exams, respectively, and the most frequent pneumatization pattern was the multilocular type in both locations. Bilateral pneumatization was more prevalent in the roof of the mandibular fossa. Considering the analysis of 60 pairs of exams, in panoramic radiography, pneumatizations in the roof of the mandibular fossa and articular eminence were identified in 22 (36.7%) and 12 (20.0%) examinations, respectively. Regarding CBCT images, pneumatizations in the roof of the mandibular fossa was observed in 24 (40.0%) exams, while articular eminence was found in 14 (23.3%) images. There were no statistically significant differences between the proportion of pneumatization identified by panoramic radiography and CBCT ( $p > 0.05$ ).

**Conclusion:** This study suggests that panoramic radiography may be an imaging method used to evaluate pneumatization in the temporomandibular joint region.

**Uniterms:** Temporal bone. Temporomandibular joint. Panoramic radiography. Cone beam computed tomography.

Submetido: 14/09/2021

Aceito: 26/01/2022

### INTRODUCTION

The development of skull bones is accompanied by the formation of air-filled cavities called pneumatizations<sup>1-5</sup>. These cavities, also defined as air cells (AC), represent anatomical variations when found in certain locations<sup>3,6</sup>. Tremble (1934)<sup>7</sup> mapped the distribution of these pneumatic areas throughout the temporal bone, finding ten different sites, including the zygomatic process<sup>2,5,8,9</sup>. Among the sites, the best

known is the temporal bone mastoid process<sup>3</sup>. There is a wide variation in the extent of this temporal pneumatization<sup>1,4,10</sup>, making some of its locations only occasional<sup>3,11</sup>. Considering the individual variations, in the zygomatic process of the temporal bone, air cells may be restricted to the mandibular fossa roof, which is called pneumatized mandibular fossa of the temporal bone (PMF), or may extend to the articular eminence, which is described as pneumatized articular eminence of the temporal bone (PAT)<sup>1,10</sup>.

**Autor para Correspondência:** Cláudia Borges Brasileiro

Avenida Presidente Antônio Carlos, 6627, Pampulha, Belo Horizonte, Minas Gerais. CEP: 31.270-901. Phone: +55 31 3409 2489.

E-mail: claudiabb@ufmg.br

An imaging approach to temporal pneumatization was primarily performed by Tyndall and Matteson, who described AC that occurred at the base of the zygomatic arch and the articular eminence of the temporal bone, which resembled AC of the hip region mastoid process and ethmoid bone<sup>1-5,12</sup>. In their study, the authors identified the pattern of manifestation of these changes, which included asymptomatic radiolucent defects in the zygomatic process of the temporal bone; anterior extension of the defect by the articular eminence, but not beyond the zygomatic-temporal suture; and no expansion or destruction of the zygomatic cortical bone. In addition, they classified the PAT, describing the pneumatization pattern as either unilocular or multilocular<sup>2,12</sup>.

AC in the articular eminence of the temporal bone can be observed in panoramic radiographs, and there are many studies on the prevalence of PAT based on this exam<sup>5,9,12,13</sup>. By contrast, other conventional skull projections do not provide an adequate visualization of the posterior zygomatic arch<sup>2,13</sup>. Thus, the panoramic radiograph was considered the initial method to evaluate these cavities, since it is a routine, inexpensive complementary exam that exposes the individual to a lower radiation dose when compared to fan beam computed tomography (FBCT) and to cone beam computed tomography (CBCT)<sup>2,4,5</sup>. However, in tomographic exams, overlapping images of anatomical structures are not observed, and the medial portion of the temporal bone can only be seen in this examination, making it more suitable for the diagnosis of AC in the temporal bone<sup>5</sup>. Moreover, with the advent of CBCT, the disadvantages of FBCT regarding high costs and higher radiation doses have been solved<sup>2</sup>. CBCT has replaced FBCT in certain situations by providing adequate image quality associated with lower radiation exposure, shorter scanning time, and fewer imaging artifacts<sup>2,14</sup>.

Knowledge about AC adjacent to the TMJ is relevant, since they represent sites of minimal resistance and facilitate the spread of inflammation, tumors, or fractures in the joint region<sup>2,12</sup>. Therefore, despite being a variant of anatomy that does not require treatment<sup>5</sup>, it is suggested that the imaging diagnosis of PMF and PAT in the TMJ region is paramount in planning any surgical procedure, considering that the presence and extension of pneumatizations may be complicating factors of these surgeries<sup>2,5,12,15-19</sup>.

This study aimed to determine the prevalence and characteristics of pneumatic spaces in the TMJ area using CBCT images, and

to compare panoramic radiography and CBCT in identifying pneumatizations in the mandibular fossa roof (PMF) and articular eminence (PAT), with CBCT as the gold standard.

## MATERIALS AND METHODS

This retrospective cross-sectional study, based on collected data, was approved by the Research Ethics Committee of the Federal University of Minas Gerais (CAAE 62546316.5.0000.5149). Panoramic radiographs and CBCT of the TMJ region from the database of a private dental radiology clinic were evaluated from January 2008 to September 2017. Complementary examinations were performed for several reasons unrelated to the present study. The present study included patients who underwent both imaging exams and patients who underwent only tomographic examination of the TMJ region. Patients with a history of maxillofacial trauma, fractures, pathological lesions in the temporal bone region, or craniofacial developmental anomalies that precluded the viewing of the mandibular fossa roof and articular eminence were excluded from the analysis<sup>1-5</sup>. Inadequate CBCT images due to the presence of artifacts or patient movement were also excluded. The interval between the two exams was up to six months.

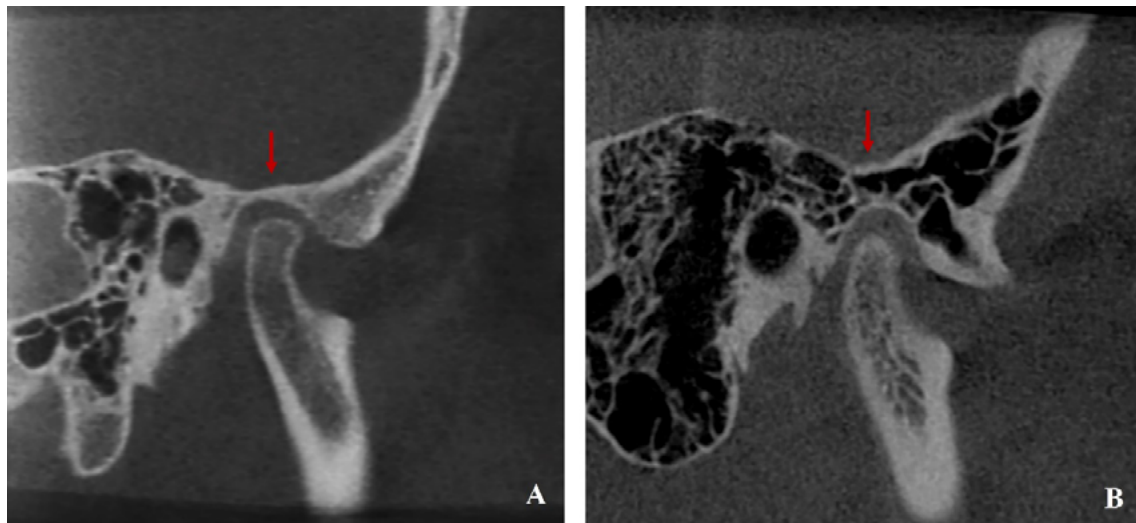
CBCT were acquired on i-CAT Classic® equipment (Imaging Sciences International Inc., Hatfield, Pennsylvania, USA), employing the following exposure factors: 0.25 mm voxel size for TMJ exams, with the patient positioned with the mouth closed or semi-open, and 0.3 mm for exams with the patient positioned with the mouth open; 160 mm to 80 mm field of view (FOV); 120 kVp pipe voltage; 36.12 mA tube current; 40 seconds of exposure for exams with the patient in the closed and semi-open mouth positions and 20 seconds in the open mouth position. CBCT images were viewed using Xoran i-CAT software and analyzed in three orthogonal planes: axial, sagittal, and coronal. Panoramic radiographs were acquired on Orthopantomograph OP200 D® equipment (Instrumentarium Dental Inc., Charlotte, North Carolina, USA) employing the following exposure factors: 85 kVp tube tension, 2 to 16 mA tube current, and 2.7 to 14.1 seconds of exposure.

Pneumatizations were classified as unilocular when a single hypodense defect was detected, well delimited by more hyperdense bone edges, or multilocular when several small hypodense cavities were identified (Figure 1)<sup>12</sup>. Additionally, laterality (unilateral or bilateral)<sup>1-5</sup>

and location (PMF or PAT) were determined<sup>1,2,4</sup>. In the present study, the roof of the mandibular fossa and temporal bone is defined as the portion of the temporal bone above the hypothetical line

drawn horizontally from the highest point of the mandibular fossa space that corresponds to the medial portion of the joint and is anterior to the mastoid process and external auditory canal.

**Figure 1.** Cone Beam Computed Tomography. Sagittal sections showing absence of pneumatization in the roof of mandibular fossa and articular eminence (A) and presence of multilocular pneumatization in these locations (B).



The exams were analyzed by an examiner who had been previously calibrated by a radiologist with 20 years of experience. The intra and interexaminer agreement obtained in the calibration process by means of the Kappa test was considered good:  $\geq 0.92$  and  $\geq 0.80$ , respectively. Agreements were calculated at the mandibular fossa and articular eminence on panoramic images and on CBCT images.

Descriptive and inferential analysis were performed (Statistical Package for the Social Science - SPSS; version 15.0; SPSS Inc., Chicago, IL, USA) with a 95% confidence interval (CI) and a p-value  $\leq 0.05$ . The age comparison between groups with and without pneumatization was performed by the nonparametric Mann-Whitney test, due to the abnormal distribution of these data (Kolmogorov-Smirnov test). Pearson's chi-square test was used to verify the association between gender and the presence of pneumatization in both sites analyzed in this study. McNemar's Chi-Square test was used to compare the differences between CBCT and panoramic radiography in the diagnosis of pneumatization.

From the initial sample of 736 CBCT exams, 31 CT scans were considered inadequate for diagnosis and were therefore excluded. Thus, the final sample included 705 scans, corresponding to 1,410 joints. A total of

60 patients also had panoramic exams. The sample profile was composed mainly of females (75.9%), with a mean age of 42.6 years (SD =  $\pm 17.4$ ), ranging from 5 to 91 years.

## RESULTS

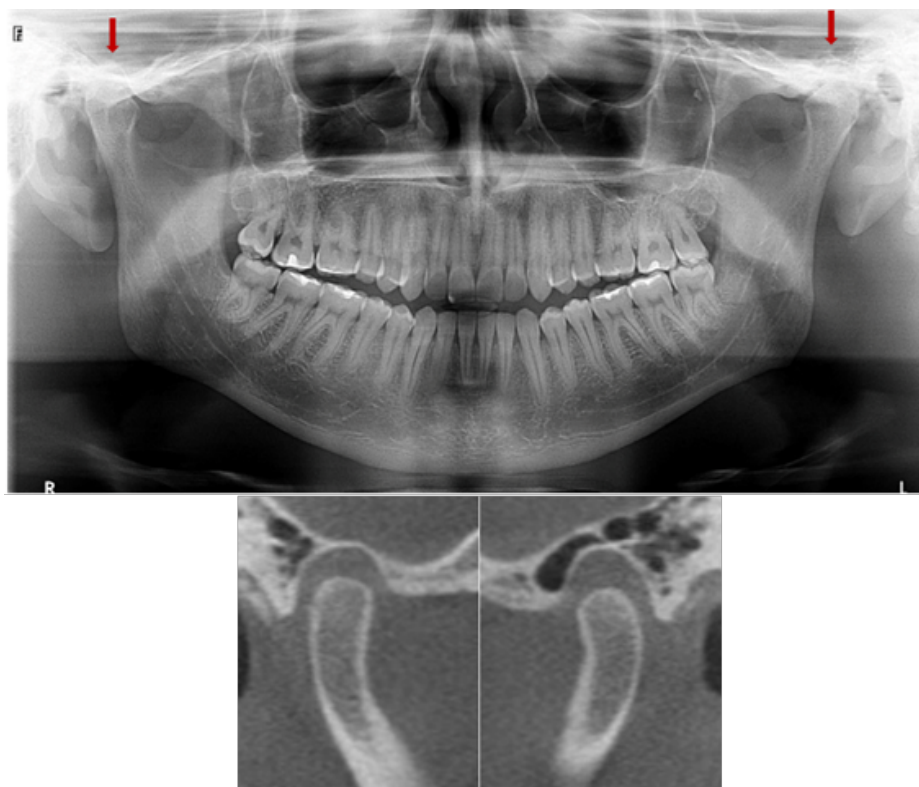
Of the 705 exams evaluated in this study, the presence of PMF and PAT on at least one side were identified in 330 (46.8%) and 154 (21.8%) exams, respectively (Table 1). Concerning laterality, PMF revealed more bilateral cases, while PAT was more frequent on only one of the evaluated sides (Table 2). The distribution of cases of PMF and PAT according to the impacted side is shown in Table 3. Considering the pattern, multilocular pneumatization was the most frequent on both sides and in both sites.

In part of the analysis (n = 60), it was possible to compare the results obtained by CBCT and panoramic radiography (Figure 2). The presence of PMF and PAT on at least one side was identified in 22 (36.7%) and 12 (20.0%) panoramic images, respectively. When using CBCT images, the results were 24 (40.0%) and 14 (23.3%) (Table 4). Comparison of the proportion of the presence of pneumatization in panoramic radiography and CBCT revealed that, in the roof of the mandibular fossa, anatomical variation was only observed in

CBCT images in 7 (29.2%) exams, while in 2 (4.3%) exams, respectively. In both locations, 5 (13.9%) exams, pneumatization was only identified in panoramic images. Regarding PAT using CBCT and panoramic radiography, pneumatization was observed in 4 (28.6%) and

no statistically significant differences were found between the proportion of pneumatization identified in the panoramic radiographs and in the CBCT images ( $p > 0.05$ ) (Table 5)

**Figure 2.** Panoramic radiograph and cone beam computed tomography showing multilocular pneumatization in the roof of mandibular fossa and articular eminence on the left side of a male patient.



**Table 1.** Frequency of pneumatization in the roof of mandibular fossa (PMF) and articular eminence (PAT) using cone beam computed tomography (CBCT).

Pneumatization	n (%)
PMF	
Present	330 (46.8)
Absent	375 (53.2)
PAT	
Present	154 (21.8)
Absent	551 (78.2)

**Table 2.** Frequency of pneumatization in the roof of mandibular fossa (PMF) and articular eminence (PAT) according to laterality using cone beam computed tomography (CBCT).

Pneumatization	n (%)
PMF	
Unilateral	146 (44.2)
Bilateral	184 (55.8)
PAT	
Unilateral	99 (64.3)
Bilateral	55 (35.7)

**Table 3.** Frequency of pneumatization in the roof of mandibular fossa (PMF) and articular eminence (PAT) according to the pneumatization pattern using cone beam computed tomography (CBCT).

Pneumatization	Unilocular n (%)	Multilocular n (%)
PMF		
Right	12 (5.2)	219 (94.8)
Left	17 (6.0)	266 (94.0)
PAT		
Right	10 (12.0)	73 (88.0)
Left	15 (11.9)	111 (88.1)

**Table 4.** Comparison between pneumatization frequency in panoramic radiography and cone beam computed tomography (CBCT) according to location.

Pneumatization	Panoramic Radiography n (%)	CBCT n (%)
PMF		
Present	22 (36.7)	24 (40.0)
Absent	38 (63.3)	36 (60.0)
PAT		
Present	12 (20.0)	14 (23.3)
Absent	48 (80.0)	46 (76.7)

**Table 5.** Proportion of presence of pneumatization in panoramic and CBCT images.

Panoramic Radiography	Cone Beam Computed Tomography					
	PMF			PAT		
	Present n (%)	Absent n (%)	p*	Present n (%)	Absent (%)	p*
PMF						
Present n (%)	17 (70.8)	5 (13.9)	0.774	---	---	0.688
Absent n (%)	7 (29.2)	31 (76.1)		---	---	
PAT						
Present n (%)	---	---		10 (71.4)	2 (4.3)	
Absent n (%)	---	---		4 (28.6)	44 (95.7)	

\*McNemar test with significance level of 5%

## DISCUSSION

In the temporal bone, there are five main pneumatization regions: the middle ear, mastoid process, peri-labyrinth, petrous apex, and accessory regions<sup>1,5,7</sup>. Due to the proximity of the TMJ to these sites, it is assumed that AC would be able to extend in some individuals from the region of the mastoid process to the base of the zygomatic arch and articular eminence of the temporal bone<sup>1,5,10</sup> through a physiological process related to periosteal activity that promotes the growth of these anatomical accidents<sup>1,20</sup>.

Thus, the identification of the presence of AC is of fundamental importance for planning surgical procedures in the TMJ or adjacent regions<sup>21,22</sup> in order to prevent adversity during the surgery and several damages to anatomical structures near to the lateral skull base<sup>4,5,12,16-19</sup>. From this perspective, Bhalchim et al.<sup>23</sup> indicate

that AC may occur more frequently in diagnosed TMJ disorder patients<sup>16</sup>, which are more susceptible to be exposed to surgical procedures in the TMJ area. Eminectomy or total replacement of TMJ for recurrent dislocation of mandible and degenerative diseases with substantial reduction of bony mass treatment, respectively, could represent a hazard to patients with PAT, due to essential flatness of articular eminence on these techniques<sup>16-19</sup>. Therefore, Costa Ribeiro et al.<sup>17</sup> performed a different technique (Dautrey's Procedure) as an alternative surgical treatment for recurrent mandibular dislocation in patients with PAT. Moreover, as sites of minimal resistance, tumors of the mastoid process and ear are more likely to extend to the TMJ region in the presence of AC, while otitis and mastoiditis may also involve the joint, promoting ankylosis<sup>2,12</sup>. Furthermore, knowledge about pneumatization is necessary to determine the differential diagnosis

with other radiolucencies that may occur in the zygomatic bone, particularly aneurysmal bone cyst, hemangioma, giant cell tumor, eosinophilic granuloma, fibrous dysplasia, or metastatic tumor deposits<sup>5</sup>. Although such pathological lesions are rare, they should be distinguished from zygomatic bone AC<sup>3</sup>.

Some studies on the prevalence of pneumatizations in the zygomatic arch of the temporal bone have been performed<sup>2-5,9,12</sup>. Several of these studies used panoramic radiography to evaluate the frequency of pneumatizations, and the values ranged from 1% to 3.42%<sup>1,9,12,13,24-27</sup>. Friederich et al.<sup>3</sup> used FBCT to evaluate AC in the zygomatic bone and found a frequency of 7.57%. Recent studies using CBCT have obtained similar results, with a frequency of 8% when exclusively examining PAT<sup>5</sup>. Ladeira et al.<sup>2</sup> and Ilguy et al.<sup>4</sup>, however, evaluated the presence of PMF and PAT separately using CBCT. Considering the PMF, the studies revealed a frequency of 38.3% and 11.7%, respectively. Regarding PAT, the results showed frequencies of 21.3% and 65.8%, respectively. In the present study, the frequency of PMF and PAT was 46.8% and 21.8%, respectively. These values were higher than those obtained in other studies, except for the frequency of PAT, whose results were similar to those in the study by Ladeira et al.<sup>2</sup>. The differences observed between the obtained data can be attributed to the methodologies used. In the present study, analogous to the research by Ladeira et al.<sup>2</sup> and Ilguy et al.<sup>4</sup>, CBCT was used to estimate the prevalence of pneumatizations, classifying them according to the location, which included pneumatizations restricted to the mandibular fossa roof and articular eminence pneumatization. However, in contrast to the two studies, in the present study, the joint roof was defined as the portion of the temporal bone above the horizontally drawn line from the highest point of the mandibular fossa space and is anterior to the mastoid process external auditory canal<sup>28</sup>. Therefore, the highest point of the articular fossa is the fixed point of the ginglymoarthrodial joint, which represents the TMJ, unlike the mandible head, if used as a reference point<sup>28</sup>. Since patients with TMJ dysfunction may have altered condylar relationships and wear, the definition of the joint roof that would correspond to the bone region of the temporal bone just above the mandible head is poorly standardized. According to Barghan et al.<sup>29</sup>, several pathological and even physiological conditions can modify the jaw head surface and temporal bone components, as well as adjacent

soft tissues. Thus, in that study, he points out that these conditions could affect the morphology and positioning of the mandible head in the mandibular fossa, producing altered relationships of the TMJ components. Therefore, CBCT is the modality of choice as the complementary exam and has been increasingly used to evaluate the bone tissue of this joint<sup>29</sup>.

Comparatively, there are other differences in methodology between more recent research and the current one. First, some studies did not subdivide pneumatizations restricted to the mandibular fossa roof from those only or concurrently affected by the articular eminence<sup>3,5</sup>. In both cases, a defect identified after the temporal zygomatic suture in the zygomatic bone was considered<sup>3,5</sup>. In addition, Friederich et al.<sup>3</sup> used FBCT as a method to analyze AC; however, its use, to the detriment of the use of CBCT, does not serve as a pretext for the observed prevalence differences, since both examinations provide three dimensional (3D) images<sup>2</sup>. However, such research showed much lower pneumatization frequency values than those obtained in the present study, which can be attributed to the sample population or the location classification used.

Analogous to the other studies mentioned, the variables of sex, age of the patient, pneumatization laterality, and topography were considered<sup>2-5</sup>. In this study, the mean age of patients was 42.6 years, which is similar to that found in the literature, which ranged from 33.4 to 49.96 years<sup>2-5</sup>. The sample age range in the present study was broad (5-91 years), as was the age range in other studies<sup>2-5</sup>. In this sense, there were no associations with statistical significance between sex and the presence of pneumatization in the temporal bone in the studies by Ladeira et al.<sup>2</sup>, Miloglu et al.<sup>5</sup>, and Friederich et al.<sup>3</sup>. By contrast, findings from Ilguy et al.<sup>4</sup> highlighted statistically significant differences for PAT, with women (73.6%) being more predisposed than men to develop PAT.

For laterality, there was a bilateral and unilateral ratio of 1.26:1 for PMF, which is consistent with that obtained by Ladeira et al.<sup>2</sup> (1.35:1). On the other hand, Ilguy et al.<sup>4</sup> found more unilateral cases for PMF (1: 3,3). Regarding PAT, the ratio between unilateral and bilateral in this study was 1.8:1, which was in accordance with findings from Ladeira et al.<sup>2</sup> (1.2:1), Miloglu et al.<sup>5</sup> (3.1:1), and Friederich et al.<sup>3</sup> (3.1:1). These results contrast with the work by Ilguy et al.<sup>4</sup>, who found a predominance of bilateral over unilateral PAT (1:1.35).

Considering patterns, in PMF and PAT the multilocular type was the most frequent on both sides, with a frequency of 92.5%, considering both locations. Similar results were observed by Ladeira et al.<sup>2</sup> (98.7%, considering both locations) and Miloglu et al.<sup>5</sup> (58.5%, considering only the articular tubercle). Ilguy et al.<sup>4</sup>, however, found a preponderance of unilocular pneumatizations (75%) for PMF.

In the present study, all 154 exams (21.8%) diagnosed with PAT also had PMF. In contrast, Ladeira et al.<sup>2</sup> and Ilguy et al.<sup>4</sup> showed CBCT images that had PAT without simultaneously presenting PMF. In this sense, it is understood that due to the mechanism of formation and development of pneumatizations, which extend from the mastoid process until reaching the articular eminence, the AC must pass, according to the temporal bone anatomy, through the mandibular fossa roof<sup>1,5,10</sup>. According to Friederich et al.<sup>3</sup>, the formation of PAT is conditioned on the presence of pneumatizations in the mandibular fossa region.

In the literature, only one study compared the accuracy between panoramic radiography and CBCT to detect pneumatizations in the zygomatic bone<sup>1</sup>. Barbosa et al.<sup>1</sup> found that panoramic radiography is not the complementary exam of choice for AC detection, based on its average to low accuracy for the diagnosis of PAT and PMF when compared to CBCT. The current study, different from Barbosa et al.<sup>1</sup>, applied a methodology-based quantitative analysis exclusively for the detection of pneumatization through different imaging exams and compared the results (McNemar test). Therefore, the objective of using this methodology is to verify if there is a difference in the frequency of identifying pneumatizations in both locations, according to the imaging exam used, assuming that CBCT is the gold standard for providing images without overlapping structures<sup>1-5</sup>.

Thus, the results indicated that there were no statistically significant differences between the proportion of pneumatizations identified in panoramic radiography and CBCT images, both in the roof of the mandibular fossa and in articular eminence ( $p > 0.05$ ). Therefore, panoramic radiographs could be used to diagnose pneumatization in the zygomatic bone, despite its two-dimensionality limitations. Since panoramic radiographs are inexpensive routine dental examinations with a lower radiation dose,<sup>1-5</sup> they often primarily indicate the presence of pneumatizations in this region<sup>2</sup>. Hence, because AC is an anatomical variation, radiographic

follow-up can be performed through this exam. However, CBCT can be used for a more accurate diagnosis in cases with a suspected anatomical accident<sup>2</sup>. Three-dimensional images should be used to determine the exact size and extent of pneumatizations and their relationship to adjacent tissues in circumstances previously detected by panoramic radiography before undergoing surgical procedures in the TMJ and accessory regions<sup>2,4</sup>.

In conclusion, the occurrence of AC in the mandibular fossa roof was greater than in articular eminence. Additionally, the prevalence of pneumatizations identified in the present study was higher than those found in the literature when considering a larger sample size. Thus, further studies with larger populations, different imaging tests, and specific patient groups are suggested to provide a more accurate overview of these pneumatic areas. Moreover, panoramic radiography may be the imaging exam of choice for the evaluation of AC in the zygomatic bone in cases of initial identification and preservation of this variation. CBCT should be employed for detailed purposes in surgical planning in the TMJ and associated regions.


## CONFLICT OF INTEREST


The authors declare no conflict of interest.


## ACKNOWLEDGMENT

This study was supported by Pró-Reitoria de Pesquisa da Universidade Federal de Minas Gerais (PRPq/UFMG).

## ORCID

Alice Souza Villar Cassimiro Fonseca  <https://orcid.org/0000-0001-5119-3760>

Loliza Chalub Luiz Figueiredo Hourí  <https://orcid.org/0000-0002-0892-9047>

Vinícius de Carvalho Machado  <https://orcid.org/0000-0002-3089-5138>

Cláudia Borges Brasileiro  <https://orcid.org/0000-0001-6691-3943>

## REFERENCES

1. Barbosa GL, Nascimento MC, Ladeira DB, Bomtorim VV, Cruz AD, Almeida SM. Accuracy of digital panoramic radiography in the diagnosis of temporal bone pneumatization: a study in vivo using cone-beam-computed

- tomography. *J Craniomaxillofac Surg.* 2014;42(5):477-81.
2. Ladeira DB, Barbosa GL, Nascimento MC, Cruz AD, Freitas DQ, Almeida SM. Prevalence and characteristics of pneumatization of the temporal bone evaluated by cone beam computed tomography. *Int J Oral Maxillofac Surg.* 2013;42(6):771-5.
  3. Friedrich RE, Viezens L, Grzyska U. Pneumatization of the zygomatic process of temporal bone on computed tomograms. *GMS Interdiscip Plast Reconstr Surg DGPW.* 2016;5:1-12.
  4. İlgüy M, Dölekoğlu S, Fişekçioğlu E, Ersan N, İlgüy D. Evaluation of pneumatization in the articular eminence and roof of the glenoid fossa with cone-beam computed tomography. *Balkan Med J.* 2015;32(1):64-8.
  5. Miloglu O, Yılmaz AB, Yildirim E, Akgul HM. Pneumatization of the articular eminence on cone beam computed tomography: prevalence, characteristics and a review of the literature. *Dentomaxillofac Radiol.* 2011;40(2):110-4.
  6. Diamant M. Size variation of the mastoid air cell system according to Wittmaack, Schwarz and Diamant. *Acta Otolaryngol.* 1954;43 Suppl 118:54-67.
  7. Tremble GJ. Pneumatization of the temporal bone. *Arch Otolaryngol.* 1934;19:172.
  8. Allam AF. Pneumatization of the temporal bone. *Ann Otol Rhinol Laryngol.* 1969;78(1):48-64.
  9. Orhan K, Delilbasi C, Cebeci I, Paksoy C. Prevalence and variations of pneumatized articular eminence: a study from Turkey. *Oral Surg Oral Med Oral Pathol Oral Radiol Endod.* 2005;99(3):349-54.
  10. Groell R, Fleischmann B. The pneumatic spaces of the temporal bone: relationship to the temporomandibular joint. *Dentomaxillofac Radiol.* 1999;28(2):69-72.
  11. Seppälä AJ. Variations in the pneumatic cell system of the temporal bone: acute otitis media and its complications in varying types of temporal pneumatization. *Acta Otolaryngol.* 1946;33 Suppl 64:1-131.
  12. Tyndall DA, Matteson SR. Radiographic appearance and population distribution of the pneumatized articular eminence of the temporal bone. *J Oral Maxillofac Surg.* 1985;43(7):493-7.
  13. Hofmann T, Friedrich RE, Wedl JS, Schmelzle R. Pneumatization of the zygomatic arch on pantomography. *Mund Kiefer Gesichtschir.* 2001;5(3):173-9.
  14. Miracle AC, Mukherji SK. Conebeam CT of the head and neck, part 1: physical principles. *AJNR Am J Neuroradiology.* 2009;30(6):1088-95.
  15. Helman J, Laufer D, Minkov B, Gutman D. Eminentomy as surgical treatment for chronic mandibular dislocations. *Int J Oral Surg.* 1984;13(6):486-9.
  16. Heim N, Götz W, Reich R, Faron A. The prevalence of pneumatized articular eminence in the temporal bone. Do we need a high resolution computed tomography-based novel risk classification for eminentomy? *J Craniomaxillofac Surg.* 2018;46(12):1996-2002.
  17. Costa Ribeiro R, Santos Jr, BJ, Provenzano N, Freitas PHL. Dautrey's procedure: an alternative for the treatment of recurrent mandibular dislocation in patients with pneumatization of the articular eminence. *Int J Oral Maxillofac Surg.* 2014;43(4):465-9.
  18. Granquist EJ, Quinn PD. Total reconstruction of the temporomandibular joint with a stock prosthesis. *Atlas Oral Maxillofac Surg Clin North Am.* 2011;19(2):221-32.
  19. Al Faleh W, Ibrahim ME. A tomographic study of air cell pneumatization of the temporal components of the TMJ in patients with temporomandibular joint disorders. *Egypt Dent J.* 2005;51:1835-42.
  20. Ojala L. Pneumatization of the bone and environmental factors: experimental studies on chick humerus. *Acta Otolaryngol, Supl.* 1957;133:3-28.
  21. Chen T, Hsu Y, Li J, Hu J, Khadka A, Wang Q et al. Correction of zygoma and zygomatic arch protrusion in East Asian individuals. *Oral Surg Oral Med Oral Pathol Oral Radiol Endod.* 2011;112(3):307-14.
  22. Tang K, Hsu Y, Hu J, Zhao Y, Wang Q, Li J. New horizontal v-shaped osteotomy for correction of protrusion of the zygoma and the zygomatic arch in East Asians: indication and results. *Br J Oral Maxillofac Surg.* 2014;52(7):636-40.
  23. Bhalchim SG, Jugade SC, Ramaswami E, Gogri AA, Kadam SG, Umarji HR. Prevalence of pneumatized articular tubercle using panoramic radiography and cone beam-computed tomography: a retrospective study. *Contemp Clin Dent.* 2018;9 Suppl 2:S221-S226.
  24. Kaugars GE, Mercuri LG, Laskin DM. Pneumatization of the articular eminence of the temporal bone: prevalence, development, and surgical treatment. *J Am Dent Assoc.* 1986;113(1):55-7.
  25. Yavuz MS, Aras MH, Güngör H, Büyükkurt MC. Prevalence of the pneumatized articular eminence in the temporal bone. *J Craniomaxillofac Surg.* 2009;37(3):137-9.



26. Orhan K, Delilbasi C, Orhan AI. Radiographic evaluation of pneumatized articular eminence in a group of Turkish children. *Dentomaxillofac Radiol.* 2006; 35(5):365-70.
27. Orhan K, Oz U, Orhan AI, Ulker AE, Delilbasi C, Akcam O. Investigation of pneumatized articular eminence in orthodontic malocclusions. *Orthod Craniofac Res.* 2010;13(1):56-60.
28. Fuentes R, Cantín M, Ottone NE, Bucchi C. Caracterización de los componentes óseos de la articulación temporomandibular: una revisión de la literatura. *Int J Morphol.* 2015;33(4):1569-76.
29. Barghan S, Tetradis S, Mallya SM. Application of CBCT for assessment of the temporomandibular joints. *Aust Dent J.* 2012;57:Suppl 1:109-18.

## Avaliação da pneumatização do osso temporal por meio de radiografia panorâmica e tomografia computadorizada de feixe cônico

**Objetivos:** Avaliar a presença e as características da pneumatização no teto da fossa mandibular e eminência articular por meio de radiografias panorâmicas (RP) e tomografias computadorizadas de feixe cônico (TCFC).

**Métodos:** Foram analisadas imagens tomográficas da ATM de 705 pacientes, sendo que 60 desses pacientes também possuíam RP. Para todos os casos foram avaliadas a presença, a lateralidade e o padrão de manifestação da pneumatização. O teste qui-quadrado foi empregado para comparar os resultados obtidos a partir das RP e das TCFC no que tange o diagnóstico das pneumatizações.

**Resultados:** A análise descritiva revelou uma amostra predominantemente feminina (75,9%) com uma média de idade de 42,6 anos ( $\pm$  17,4). A pneumatização no teto da fossa mandibular e eminência articular foi evidenciada em 330 (46,8%) e 154 (21,8%) imagens de TCFC, respectivamente, e o padrão de pneumatização mais frequente foi o multilocular em ambas as regiões. A pneumatização bilateral foi mais prevalente no teto da fossa mandibular. Considerando a análise dos 60 pares de exames, nas radiografias panorâmicas as pneumatizações no teto da fossa mandibular e eminência articular foram identificadas em 22 (36,7%) e 12 (20,0%) exames, respectivamente. Em relação às imagens tomográficas, a presença desse achado no teto da fossa foi observada em 24 (40,0%) exames e na eminência articular em 14 (23,3%). Não houve diferença com significância estatística entre a proporção de pneumatização identificada em RP e TCFC ( $p > 0,05$ ).

**Conclusão:** Os resultados obtidos sugerem que a radiografia panorâmica pode ser um método de diagnóstico por imagem empregado para avaliação de pneumatizações na região da ATM.

**Descritores:** Osso temporal. Articulação temporomandibular. Radiografia panorâmica. Tomografia computadorizada de feixe cônico.